

IDIOPATHIC CRYOGLOBULINEMIC VASCULITIS AS A CAUSE OF THROMBOTIC MICROANGIOPATHY

Milanović Matea¹, Kasumović Dino¹, Šenjug Petar^{2,3}, Torić Luka¹, Zagorec Nikola¹, Galešić Krešimir¹, Horvatić Ivica^{1,4}, Galešić Ljubanović Danica^{2,3}

¹Department of Internal Medicine, Division of Nephrology and Dialysis, University Hospital Dubrava, Zagreb, Croatia

²Department of Nephropathology and Electron Microscopy, University Hospital Dubrava, Zagreb, Croatia

³Institute of Pathology, University of Zagreb School of Medicine, Zagreb, Croatia

⁴University of Zagreb School of Medicine, Zagreb, Croatia

An 83-year-old male patient presented with **rash, edema and hemoptysis** in another hospital center. Laboratory signs showed **acute kidney injury, microhematuria, proteinuria and pancytopenia**. In the patient's history there were no significant chronic diseases. Kidney biopsy was performed and revealed **thrombotic microangiopathy**. Immunological findings (ANA, anti-dsDNA, ENA 6, antiphospholipid antibodies, p/c-ANCA, anti-GBM) were negative, as well as serology of HIV, hepatitis B and C. Stool samples were negative for Shigella and Salmonella and ADAMTS13 enzyme activity was within normal range. Lung biopsy indicated thickening of septa without hemorrhage. Renopulmonary syndrome was suspected, and the patient was treated with corticosteroids and cyclophosphamide. Since the patient's condition was not improving, he was transmitted to our tertiary center.

Because of the patient's state and incoherent results of the first biopsy analysis, kidney biopsy was repeated and revealed **membranoproliferative glomerulonephritis with extracapillary proliferation combined with active thrombotic microangiopathy** (Figure 1). Cytological analysis of bone marrow sample was normal and peripheral blood smears discovered few schistocytes. Levels of **cryoglobulins, rheumatoid factor and free IgM kappa chains** were high, levels of **C3** were slightly lower, whereas **C4** was extremely low. **Cryoglobulinemia type II** was found and primary TMA was excluded considering further analysis of complement parameters.

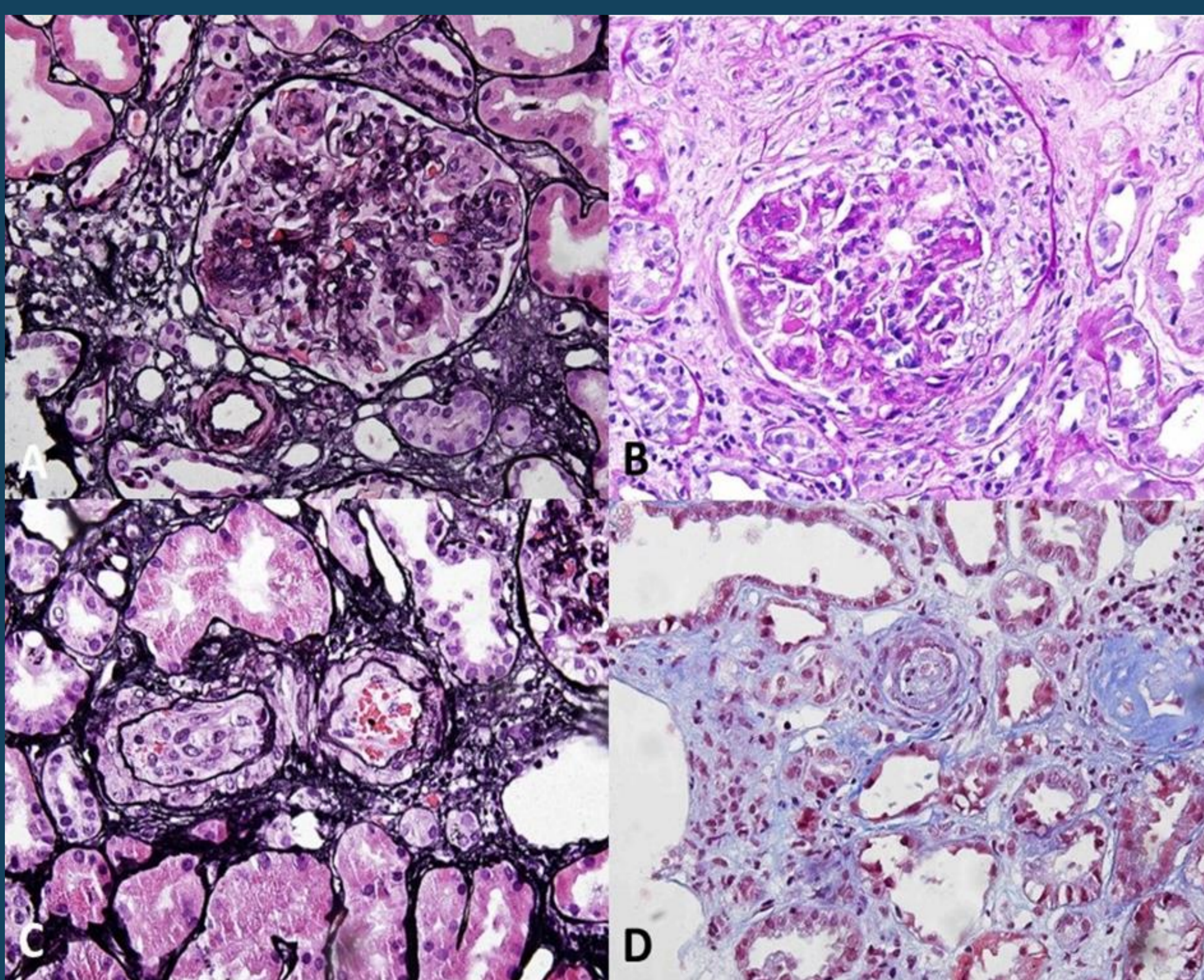


Figure 1. A) Glomerulus with membranoproliferative pattern. Jones methenamine silver, original magnification x400 B) Glomerulus with cellular crescent and hyaline thrombus. PAS stain, original magnification x400 C) Thrombus in arteriole, Jones methenamine silver, original magnification x400 D) Organized thrombus in arteriole, Masson trichrome staining, original magnification x400.

Considering **skin and lung involvement**, diagnosis of **idiopathic cryoglobulinemic vasculitis** was established and thereafter the patient was treated with one **plasmapheresis** and then 2 doses of **rituximab**. In the follow-up period renal function moderately improved, edema and rash diminished and quality of patient's life was better. In conclusion, cryoglobulinemic vasculitis, although rare, may cause thrombotic microangiopathy and only **detailed workup** can lead to proper diagnosis and treatment.